

## Evaluation of the Posterior Tibial Artery Perforator Flaps in the Management of Leg, Ankle and Foot Soft Tissue Defects

MOGHAZY A.M., M.D.; ABBAS A.H., M.D.; ADLY O.A., M.D.; EL-BADAWY M.A., M.D.; ALI O.S., M.D. and GOMAA A.A., M.Sc.

*The Department of General Surgery, Plastic and Reconstructive Surgery Unit, Faculty of Medicine, Suez Canal University, Ismailia, Egypt*

### ABSTRACT

**Background:** Reconstruction of the lower limb remains challenging and difficult, especially the lower third of the leg and the foot. Free tissue transfer was the first choice for reconstruction of these areas requiring special experience and equipment. Islanded posterior tibial artery perforator flap offered a good solution for reconstruction of these areas.

**Methods:** The study was performed on 20 patients presented with soft tissue defect in the leg, the ankle and the foot in Suez Canal University Hospital. Posterior tibial perforator flaps were islanded only on perforator vessels which were marked preoperatively by hand Doppler (8 MHz). Complications of the flap are recorded with their relation to other factors.

**Results:** The flap was done in 20 patients suffering from small to medium sized soft tissue defects in the leg (40%), the ankle (40%) and the foot (20%). The defects were due to acute causes e.g. motor accident or old conditions. Twenty flaps were islanded only on posterior tibial artery perforator-propeller design. Flaps size ranged from 28cm<sup>2</sup> to 66cm<sup>2</sup> with angle of rotation 90°-180°. Main complications occurred in 7 cases (35%) including venous congestion (5%), partial necrosis (20%) and total failure (10%). Complications related significantly to smoking and timing of intervention.

**Conclusion:** The flap with propeller design is reliable and cover defects in different sites of the leg, the ankle and the foot. The operation was relatively quick and suitable for multiple injured with possibility of regional anesthesia. The flap has same color and texture of tissue surrounding the defect giving acceptable cosmetic appearance.

**Key Words:** *Posterior tibial artery – Perforator flap – Lower limb reconstruction – Propeller.*

### INTRODUCTION

The complex soft tissue defects of the lower limb are common and their management remains challenging and difficult. The distal third of the leg and the foot are considered the most difficult areas to reconstruct due to the lack of both local skin laxity and muscular tissue [1]. Tissue transfer

and free flaps had become one of the main reconstructive options for the lower limb reconstruction, specially the lower third [2]. However, free-tissue transfer is a complex surgery and not ideal for patients with multiple co-morbidities because of long operation time which is correlated with the development of postoperative complications. Moreover, free flaps need special equipments and experiences to be carried out [3]. Some local flaps were developed like fasciocutaneous and myocutaneous flaps for lower limb reconstruction but with some restriction in the lower third of the leg and the foot [4,5]. With the development of perforator flaps, newer and more reliable flaps have become available for lower limb reconstruction [6]. With the concept of angiosomes, almost all the tissues of an angiosome can be harvested on one adequate perforator vessel which can be used as local or free flaps [7]. Wu et al., and Koshima et al., showed the perforators of the posterior tibial artery on the leg and ankle region and defined their distribution according to the zones and as well as their sizes and clinical usability [8,9]. The islanded Posterior Tibial Artery Perforator Flap (PTAPF) are used to cover small to moderate defects in the leg, heel, and foot. The posterior tibial artery perforators are consistently the largest and easiest to dissect in the leg. The flap can be pedicled or islanded and rotated up to 180 degrees, to be proximally or distally based thus enabling reconstruction variety of lower limb defects. Flap harvest is relatively quick, and the recipient site has nearly similar texture, thickness and pliability. V-Y or propeller flap designs may enable primary closure of donor site. The posterior tibial artery, which is the dominant source of blood supply of the foot, is preserved and microvascular anastomosis is obviated [6,10-16].

## PATIENTS AND METHODS

Prospective case series study was conducted on 20 patients who came to Sues Canal University complaining of soft tissue defect in the leg, the ankle and the foot. Patients with lower limb ischemia with absent distal pulsations, having injury to posterior tibial artery or degloving injury to medial side of the leg were excluded from the study.

### *Flap design:*

Perforators of the posterior tibial artery were marked using hand held Doppler (8 MHz). The nearest and largest perforator was marked and propeller flap was designed with pivot point on the selected perforator Fig. (1).

### *Surgical technique:*

The limb was exsanguinated with tight tournique. A limited exploratory initial anterior or posterior incision was made through which the perforators were identified by direct visualization, emerging through the medial intermuscular septum or through the muscles e.g. soleus and gastrocnemius muscle. If the perforator were of sufficient caliber, the anterior and posterior flap incisions would be completed and the flap was raised from proximal to distal in the subfascial plane (fasciocutaneous), identifying and preserving all of the perforators encountered, leaving the flap bridges proximally and distally.

The largest suitable distal perforator (nearest to the defect) was selected and micro-clamps were placed on all other perforators. If flap perfusion was reliable, the other perforators were ligated and the proximal incision was made. The flap was only islanded if bleeding at the tip could be demonstrated. After islanding, the septum around the perforator was gently released with division of all side muscular branches and fascial strands at minimum of 2cm diameter around the perforator to allow rotation of the flap up to 180 degrees in both directions choosing the smaller angle of rotation. The flap could be islanded on two adjacent perforators in cases which the angle of rotation was small enough to avoid kinking of the perforators. Donor could be closed primary or by skin graft Fig. (2).

## RESULTS

The study was conducted on 20 patients. Their age ranged from 7 to 55 years with mean  $\pm$  SD age  $26.25 \pm 12.74$  years. Most of the patients were males 75%. The most common cause of soft tissue defect was acute trauma (65%) due to road traffic accidents, direct trauma and fall from (Table 1). Thei-

njuries of the lower limb were in the leg (40%), around the ankle (40%) and the foot (20%). The defect size ranged from small size (65%) to medium size (35%) (Table 2).

Twenty propeller Fasciocutaneous flaps were successfully raised, 18 flaps were islanded on single perforator. Two flaps were islanded on 2 perforators for each. Most of the islanded perforators were septocutaneous (81.8%) especially in the lower third of the leg. The distance of the selected perforator from medial malleolus ranged from 3-28cm with mean value  $9.7 \text{ cm} \pm 7.38$ . The surface area of the flap ranged from  $28 \text{ cm}^2$  (7cm X 4cm) to  $66 \text{ cm}^2$  (6cm X 11cm) with mean value  $49.2 \pm 11.88$ . The angle of rotation ranged from 90 to 180° with mean value  $146.5 \pm 27.01^\circ$ . The total duration of operations (with the orthopedic team) ranged from 1-5 hours with mean value  $3.5 \pm 1.14$  hours. The exact duration of the flap operation ranged from 1-2 hours with mean value 1.4 hours. There was a significant relation between the duration of operations and the hospital stay which ranged from 1-5 weeks with mean value  $16.2 \pm 7.36$  days.

Main complications were encountered in 7 cases (35%), in form of total necrosis (10%), partial (tip) necrosis (20%) and venous congestion 1 (5%) (Table 3). The two cases of total necrosis required surgical debridement and cover by skin graft in the distal half of the foot and soleus flap in the middle third of the leg.

The 2 cases of flap failure were smokers. One flap was based on perforator in the middle third of the leg near the injury zone in middle third with fracture both bone of the leg Gust. IIIa and the wound was contaminated. The tip necrosis was 0.5 to 2cm from the tip which separated spontaneously or by surgical debridement and healed by secondary intention without affecting the result of coverage. The case of venous congestion was treated conservatively within 1 week.

Other simple complications occurred in form of simple infection 5 (25%) and edema 2 (10%) which were treated conservatively and didn't affect the flap.

Complications were significantly correlated to the time of intervention. The highest rate of complications was 85.7% and encountered in the period from 3 to 21 days after trauma (6 out of 7 cases) (Table 4).

Seven patients of studied group were smokers and all of them suffered from complications. There is significant relation between flap size and com-

plications. Complications were significantly high when flaps size increased from 51-60cm<sup>2</sup>. Total necrosis occurred when the flap size was 56cm<sup>2</sup> and 66cm.

### Case Report:

#### Case 1:

Male patient, 9 years old presented with raw area 7 X 4cm on medial side of the right ankle with exposed medial malleolus. Posterior tibial artery perforator fasciocutaneous flap was designed based on a perforator 5cm from the medial malleolus. The flap was 5 X 12cm with rotation angle of 170°. Donor site was covered by skin graft Fig. (2).

Table (1): Distribution of different causes of soft tissue defect (N=20).

Cause of injury	Number	Percentage
<i>Acute trauma:</i>		
RTA	9	45
Direct trauma	2	10
Fall from height	2	10
<i>Chronic conditions:</i>		
Old trauma	4	20
Old burn	3	15

Table (2): Distribution of studied group according to defect size (N=20).

Defect size	Number (%)
Small ≤20cm <sup>2</sup>	13 (65%)
Medium ≤50 & >20cm <sup>2</sup>	7 (35%)
Large >50cm <sup>2</sup>	0

Table (3): Complications and final outcome of the flaps (N= 20).

Complication	Number	Percentage	Intervention	Outcome
Total necrosis	2	10	Surgical	Failure of cover
Tip necrosis	4	20	Medical	Complete cover
Venous congestion	1	5	Medical	Complete cover
Total	7	35	• 5 medical • 2 surgical	• 18 complete cover • 2 failure

Table (4): Relation between timing of intervention and total complications (minor and major).

Timing of intervention	No.	Frequency of complications	p-value
1-3 days	5	3 (60%)	0.01*
3-21 days	7	6 (85.7%)	0.04*
21 days-6 months	4	3 (75%)	0.01*
>6 months	4	2 (50%)	0.2

\*: There was a statistical significant difference ( $p$ -value <0.05).

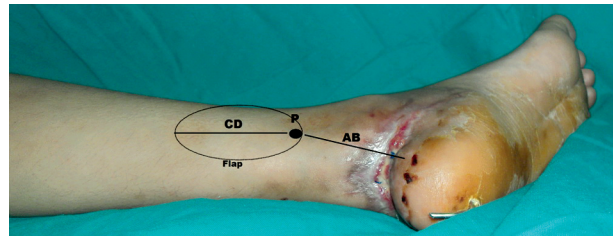


Fig. (1): Flap design. The distance between the selected perforator (P) and the proximal flap edge (CD) should equal the distance between the perforator and the distal limit of the defect (AB).

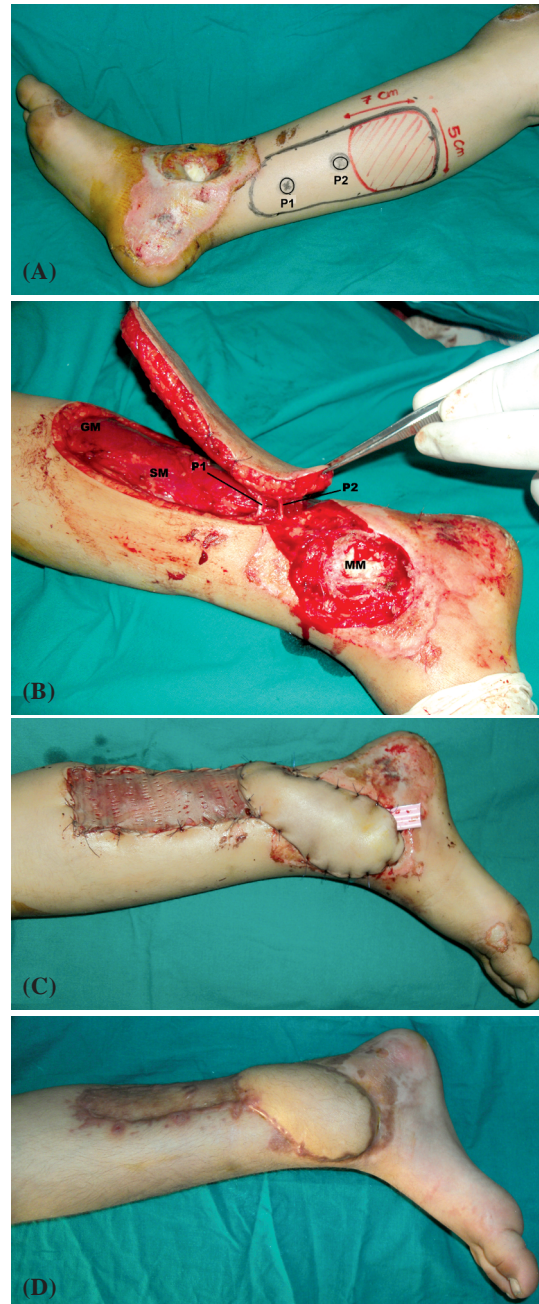


Fig. (2): Steps of posterior tibial perforator flap harvesting. A: Defect 5cm X 7cm in the medial side of the ankle with exposed bone. 2 perforators are marked by hand Doppler p1 & p2. Propeller flap 5 X 12cm was designed. B: The flap is islanded on 2 adjacent perforators P1 & P2, one of them were ligated. C: Immediate post operative view of the flap which rotated 170° to reach the defect. Flap was sutured in place with drain. Donor site was covered by split skin graft. D: View of the flap 5 weeks postoperative.



## DISCUSSION

The current study revealed that the indications for PTAP flap were soft tissue defects caused by acute trauma (65%) due to road traffic accidents (45%), fall from height (10%) and direct trauma (10%). Chronic conditions were (35%) resulted from excision of unstable or contracted scars due to old trauma or burn.

Schaverien et al., [14], reported that most of soft tissue defects were caused by high energy acute trauma in the form of road traffic accidents, fall from height, industrial and direct trauma (63%). Chronic conditions like old burn or trauma were (27%).

In this study; the associated injuries were fractures (medial malleolus and both bone leg) 8 (40%). Tendon injuries including tendon Achilles were found in 3 cases (15%). According to Schaverien et al., 2010 [14]; most of the cases were associated with fractures of the leg bones and both malleoli (88%).

In this study; the PTAP flap was used to reconstruct the leg (40%), around the ankle (40%) and the foot (20%). Most authors used the islanded PTAP flap to reconstruct the leg, the ankle and the foot with highest prevalence of injuries in the lower third of the leg [8,10,11,13-18]. Moreover Sananpanich et al., [19], used the flap to cover knee region.

All the flaps were fasciocutaneous and used to cover shallow small to medium sized defects. Deep defects usually were large with no available adjacent perforators requiring another option. Schaverien et al., and Robotti et al., [14,16]; used fasciocutaneous PTAP flaps to cover small to medium sized shallow defects.

The size of the flaps that we designed, ranged from 28cm<sup>2</sup> (4cm X 7cm) to 66cm<sup>2</sup> (6cm X 11cm) with mean value 49.2±11.88cm<sup>2</sup> without restriction in width to length ratio. Flap size differed according to defect site and size. Taylor and Pan, suggests that all posterior tibial artery territory can be harvested on single perforator [7]. Schaverien et al., have successfully raised a large flap up to 10cm of the popliteal skin crease extending from the tibia anteriorly to midline of posterior surface of the leg [14]. Koshima et al., raised 13 X 19cm flap [8].

We found that main complications occurred in 7 cases (35%) including; venous congestion in 1 case (5%) and partial flap loss (tip necrosis) were

in 4 cases (20%). Total flap necrosis occurred in 2 cases (10%). Schaverien et al., reviewed 106 PTAP flaps. Complications occurred in 45.5% of the flaps. Infection and osteomyelitis occurred in 12.5%. Non union occurred in 9%. Hematomas occurred in 3.7%. Partial flap failure occurred in 12%. Complete loss of the flap occurred in 8.5% [14]. Tos et al., 2011; performed 13 PTAP flaps. Complications occurred in 5 cases (38.5%). Flap edema occurred in 1 case (7.7%). Venous congestion occurred in 1 case (7.7%). Partial necrosis occurred in 2 cases (15.8%). Total necrosis occurred in 1 case (7.7%) [20].

In this study; the early intervention in acute stage (1<sup>st</sup> 3 days) was associated with 60% complications. While intervention in subacute phase (3-21 days) was associated with more complications (85.7%). Flap failure occurred when intervention was done after 10 days and 1 month. Godina, 1986 and Gopal et al., 2000; also reported higher complications rate, when surgical intervention was after 72 hours after injury in form of infection flap necrosis and non union [21,22].

In our study, the frequency of complications increased significantly with the flap size. The flap sizes in cases of total necrosis were 56cm<sup>2</sup> and 66cm. Many authors raised successfully large PTAP flaps islanded only on perforator vessels to reach different sites of the leg and the foot [8,20]. Taylor and Pan, 1998; suggested that all posterior tibial artery territory can be raised safely on single perforator [7]. Ozdemir et al., 2006; used the PTAP flap in 8 patients. The largest 3 flaps suffered from complications and resolved with medical treatment [10].

### Conclusion:

The islanded PTAP fasciocutaneous flaps with propeller design are reliable flaps. The Flap used successfully (90%) to cover defects in different sites of the leg, the ankle and the foot which were previously covered by free flaps. The operation was relatively quick and suitable for multiple injured and co-morbid patients with possibility of regional anesthesia. The flap has same color and texture of tissue surrounding the defect and the donor sites were small and closed by skin grafts giving acceptable cosmetic appearance. Complications related significantly to smoking, contamination state of the wound, timing of intervention and the size of the flap. The flap was good in controlling local infection of the defect site with proper antimicrobial, good dressing and debridement.

## REFERENCES

- 1- Pinsolle V., Reau A.F., Pelissier P., Martin D. and Baudet J.: Soft-tissue reconstruction of the distal lower leg and foot: Are free flaps the only choice? Review of 215 cases. *Journal of plastic, reconstructive & aesthetic surgery: J.P.R.A.S.*, 59 (9): 912-17; discussion 918. Doi: 10.1016/j.bjps.2005.11.037, 2006.
- 2- Heller L. and Levin L.S.: Lower extremity microsurgical reconstruction. *Plastic and reconstructive surgery* 108, (4): 1029-41; quiz 1042, 2001.
- 3- Jones N.F., Jarrahy R., Song J.I., Kaufman M.R. and Markowitz B.: Postoperative medical complications-not microsurgical complications-negatively influence the morbidity, mortality, and true costs after microsurgical reconstruction for head and neck cancer. *Plastic and reconstructive surgery*, 119 (7): 2053-60. Doi:10.1097/01.prs.0000260591.82762.b5, 2007.
- 4- Fix R.J. and Vasconez L.O.: Fasciocutaneous flaps in reconstruction of the lower extremity. *Clinics in plastic surgery*, 18 (3): 571-82, 1991.
- 5- Mathes S.J. and Nahai F.: Classification of the vascular anatomy of muscles: Experimental and clinical correlation. *Plastic and reconstructive surgery*, 67 (2): 177-87, 1981.
- 6- Blondeel P.N.: Perforator flaps: Anatomy, technique and clinical applications. *Quality Medical Pub.*, St. Louis, Mo, 2006.
- 7- Taylor G.I. and Pan W.R.: Angiosomes of the leg: Anatomic study and clinical implications. *Plastic and reconstructive surgery*, 102 (3): 599-616; discussion 617-598, 1998.
- 8- Koshima I., Moriguchi T., Ohta S., Hamanaka T., Inoue T. and Ikeda A.: The vasculature and clinical application of the posterior tibial perforator-based flap. *Plastic and reconstructive surgery*, 90 (4): 643-9, 1992.
- 9- Wu W.C., Chang Y.P., So Y.C., Yip S.F. and Lam Y.L.: The anatomic basis and clinical applications of flaps based on the posterior tibial vessels. *British journal of plastic surgery*, 46 (6): 470-9, 1993.
- 10- Ozdemir R., Kocer U., Sahin B., Oruc M., Kilinc H. and Tekdemir I.: Examination of the skin perforators of the posterior tibial artery on the leg and the ankle region and their clinical use. *Plastic and reconstructive surgery*, 117 (5): 1619-30. Doi:10.1097/01.prs.0000206957.02510.40, 2006.
- 11- Parrett B.M., Winograd J.M., Lin S.J., Borud L.J., Taghinia A. and Lee B.T.: The posterior tibial artery perforator flap: An alternative to free-flap closure in the comorbid patient. *Journal of reconstructive microsurgery*, 25 (2): 105-9. Doi: 10.1055/s-0028-1090616, 2009.
- 12- Saint-Cyr M., Schaverien M.V. and Rohrich R.J.: Perforator flaps: History, controversies, physiology, anatomy, and use in reconstruction. *Plastic and reconstructive surgery*, 123 (4): 132e-145e. Doi:10.1097/PRS.0b013e31819f2c6a, 2009.
- 13- Schaverien M. and Saint-Cyr M.: Perforators of the lower leg: Analysis of perforator locations and clinical application for pedicled perforator flaps. *Plastic and reconstructive surgery*, 122 (1): 161-70. Doi: 10.1097/PRS.0b013e3181774386, 2008.
- 14- Schaverien M.V., Hamilton S.A., Fairburn N., Rao P. and Quaba A.A.: Lower limb reconstruction using the islanded posterior tibial artery perforator flap. *Plastic and reconstructive surgery*, 125 (6): 1735-43. Doi: 10.1097/PRS.0b013e3181ccdc08, 2010.
- 15- Wei F.C. and Mardini S.: *Flaps and reconstructive surgery*. Saunders, [Edinburgh], 2009.
- 16- Robotti E., Carminati M., Bonferraro P.P., Bocchiotti M.A., Ortelli L., Devalle L. and Righi B.: "On demand" posterior tibial artery perforator flaps: A versatile surgical procedure for reconstruction of soft tissue defects of the leg after tumor excision. *Annals of plastic surgery*, 64 (2): 202-9. Doi: 10.1097/SAP.0b013e3181a14775, 2010.
- 17- Shalaby H.A.: The blood supply of the posterior tibial perforator-based flap. *Plastic and reconstructive surgery*, 93 (2): 440, 1994.
- 18- Teo T.C.: The propeller flap concept. *Clinics in plastic surgery*, 37 (4): 615-26, vi. Doi: 10.1016/j.cps.2010.06.003, 2010.
- 19- Sananpanich K., Tu Y.K., Kraissarin J. and Chalidapong P.: Reconstruction of limb soft-tissue defects: Using pedicle perforator flaps with preservation of major vessels, a report of 45 cases. *Injury* 39 Suppl., 4: 55-66. Doi: 10.1016/j.injury.2008.08.032, 2008.
- 20- Tos P., Innocenti M., Artiaco S., Antonini A., Delcroix L., Geuna S. and Battiston B.: Perforator-based propeller flaps treating loss of substance in the lower limb. *Journal of orthopaedics and traumatology: Official journal of the Italian Society of Orthopaedics and Traumatology*, 12 (2): 93-99. Doi: 10.1007/s10195-011-0136-0, 2011.
- 21- Godina M.: Early microsurgical reconstruction of complex trauma of the extremities. *Plastic and reconstructive surgery*, 78 (3): 285-92, 1986.
- 22- Gopal S., Majumder S., Batchelor A.G., Knight S.L., De Boer P. and Smith R.M.: Fix and flap: The radical orthopaedic and plastic treatment of severe open fractures of the tibia. *The Journal of bone and joint surgery British volume*, 82 (7): 959-66, 2000.